

Iatrogenic central retinal artery occlusion following retrobulbar anesthesia with adrenaline for vitreoretinal surgery : a case report

Confalonieri, Filippo; Ladstein, Gunn Elin; Stene-Johansen, Ingar; Petrovski, Goran

Source / Izvornik: **Journal of Medical case Reports, 2022, 16**

Journal article, Published version

Rad u časopisu, Objavljena verzija rada (izdavačev PDF)

<https://doi.org/10.1186/s13256-022-03518-0>

Permanent link / Trajna poveznica: <https://um.nsk.hr/um:nbn:hr:266:387108>

Rights / Prava: [In copyright](#) / [Zaštićeno autorskim pravom.](#)

Download date / Datum preuzimanja: **2024-05-11**



Repository / Repozitorij:

[University Hospital of Split Digital Repository](#)




CASE REPORT

Open Access



Iatrogenic central retinal artery occlusion following retrobulbar anesthesia with adrenaline for vitreoretinal surgery: a case report

Filippo Confalonieri^{1,2,3*} , Gunn Elin Ladstein¹, Ingar Stene-Johansen¹ and Goran Petrovski^{1,2,4}

Abstract

Background: We describe a patient presenting with central retinal artery occlusion (CRAO) of the right eye after retrobulbar anesthesia with adrenaline for macular pucker surgery.

Case presentation: The patient, a 67-year-old Caucasian man, developed a CRAO postoperatively by the next-day control likely due to the retrobulbar injection of a combination of Xylocaine and Bupivacaine with adrenaline as anesthetic.

Conclusions: The addition of adrenaline to the standard anesthetic solution could be a risk factor for serious complications, such as CRAO.

Keywords: Ophthalmology, Retina, Central retinal artery occlusion, Anesthesia, Adrenaline, Ocular surgery

Background

Central retinal artery occlusion (CRAO) has been reported as a rare complication associated to intraocular surgery in different types of ophthalmic surgery [1–4]. CRAO associated to anesthesia administration has been reported after sub-tenon [5, 6], peribulbar [7–11] and especially retrobulbar injection [2, 12–16]. Visual recovery is consistently reported to be poor in these patients. Epinephrine (adrenaline) is usually injected either with lidocaine or its derivatives to prolong the effects of a local anesthetic. Adrenaline is generally recognized as also having a vasoconstrictive effect that decreases bleeding and counteracts the vasodilator effects of lidocaine through its sympathectomy effect. Eye vessels appear to

be no exception even when anesthesia is administered outside the orbit [17–22]. Here, we report a case of a 1-day postoperative unilateral CRAO after vitreoretinal surgery with anesthetic containing adrenaline delivered by retrobulbar injection.

Case presentation

A 67-year-old Caucasian man with a history of non-pathological myopia underwent uneventful surgery for macular pucker with epiretinal membrane (ERM) peeling in his left eye. Three months later, he underwent the same surgical procedure using the same retrobulbar anesthesia in his right eye. Preoperative best corrected visual acuity (BCVA) was 0.5 (– 1.25 sphere – 0.75 cylinder at axis 50) in the right eye and 0.75 (– 3.25 sphere – 1.75 cylinder at axis 95) in the left eye. Both eyes were pseudophakic at the time of macular pucker diagnosis and underwent the same procedure 3 months apart. The patient underwent surgery under monitored anesthesia care with a retrobulbar block using a 25-gauge (G), 38-mm Atkinson needle

*Correspondence: filippo.confalonieri01@gmail.com

¹ Department of Ophthalmology, Oslo University Hospital, Kirkeveien 166, 0450 Oslo, Norway
Full list of author information is available at the end of the article



© The Author(s) 2022. **Open Access** This article is licensed under a Creative Commons Attribution 4.0 International License, which permits use, sharing, adaptation, distribution and reproduction in any medium or format, as long as you give appropriate credit to the original author(s) and the source, provide a link to the Creative Commons licence, and indicate if changes were made. The images or other third party material in this article are included in the article's Creative Commons licence, unless indicated otherwise in a credit line to the material. If material is not included in the article's Creative Commons licence and your intended use is not permitted by statutory regulation or exceeds the permitted use, you will need to obtain permission directly from the copyright holder. To view a copy of this licence, visit <http://creativecommons.org/licenses/by/4.0/>. The Creative Commons Public Domain Dedication waiver (<http://creativecommons.org/publicdomain/zero/1.0/>) applies to the data made available in this article, unless otherwise stated in a credit line to the data.

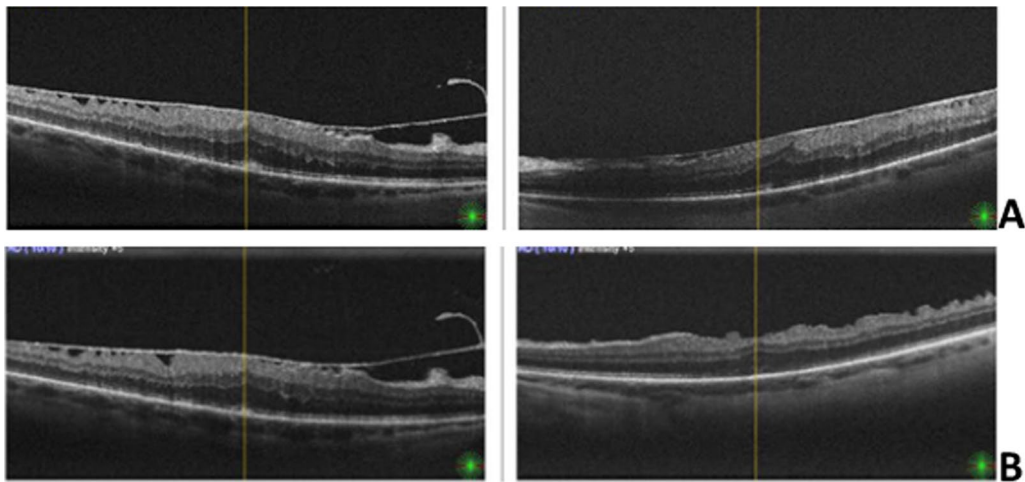


Fig. 1 One day after uncomplicated left eye pars plana vitrectomy (PPV) + epiretinal membrane (ERM) peeling procedure. **a** Preoperative cross-sectional optical coherence tomography (OCT) scan of both eyes showed macular ERM. **b** Three months postoperative cross-sectional OCT scan of the left eye shows release of ERM-related anteroposterior traction

containing 5 ml of a 1:1 mixture of 2% Xylocaine containing adrenaline (1:200,000) and Bupivacaine 5 mg/ml. Both eyes were operated by the same experienced surgeon. In

both cases the retrobulbar anesthesia was administered by the same experienced ophthalmologist and the same drug combination was used.

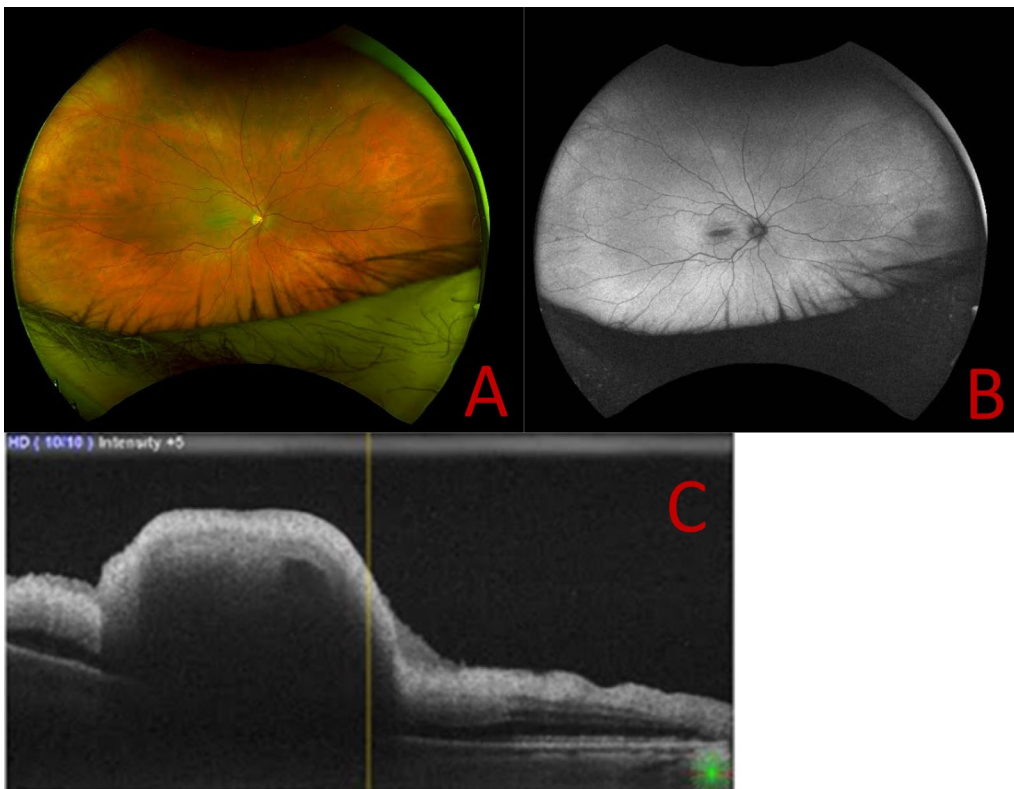


Fig. 2 Right eye central retinal artery occlusion (CRAO) 1 day after uncomplicated PPV + ERM peeling procedure. **a** One-day postoperative wide-field fundus photograph of right eye showed CRAO. **b** One-day postoperative fundus autofluorescence. **c** One-day postoperative macular cross-sectional OCT shows foveal ischemia and edema

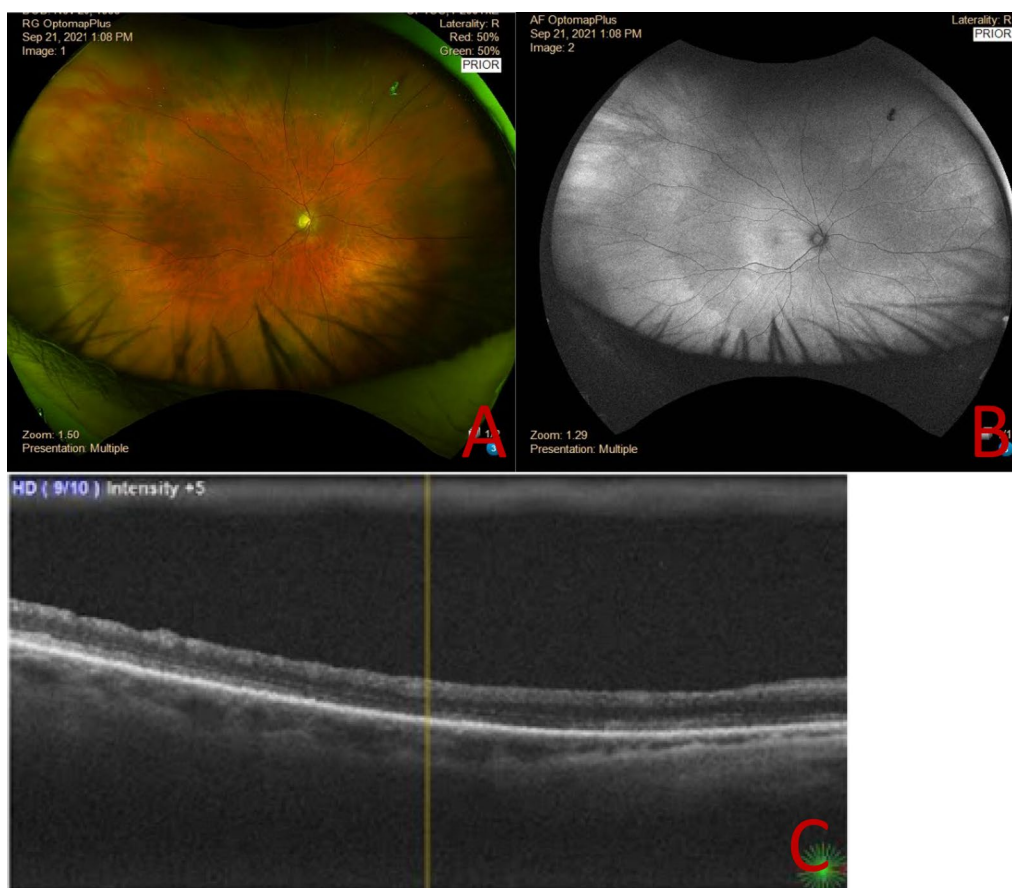
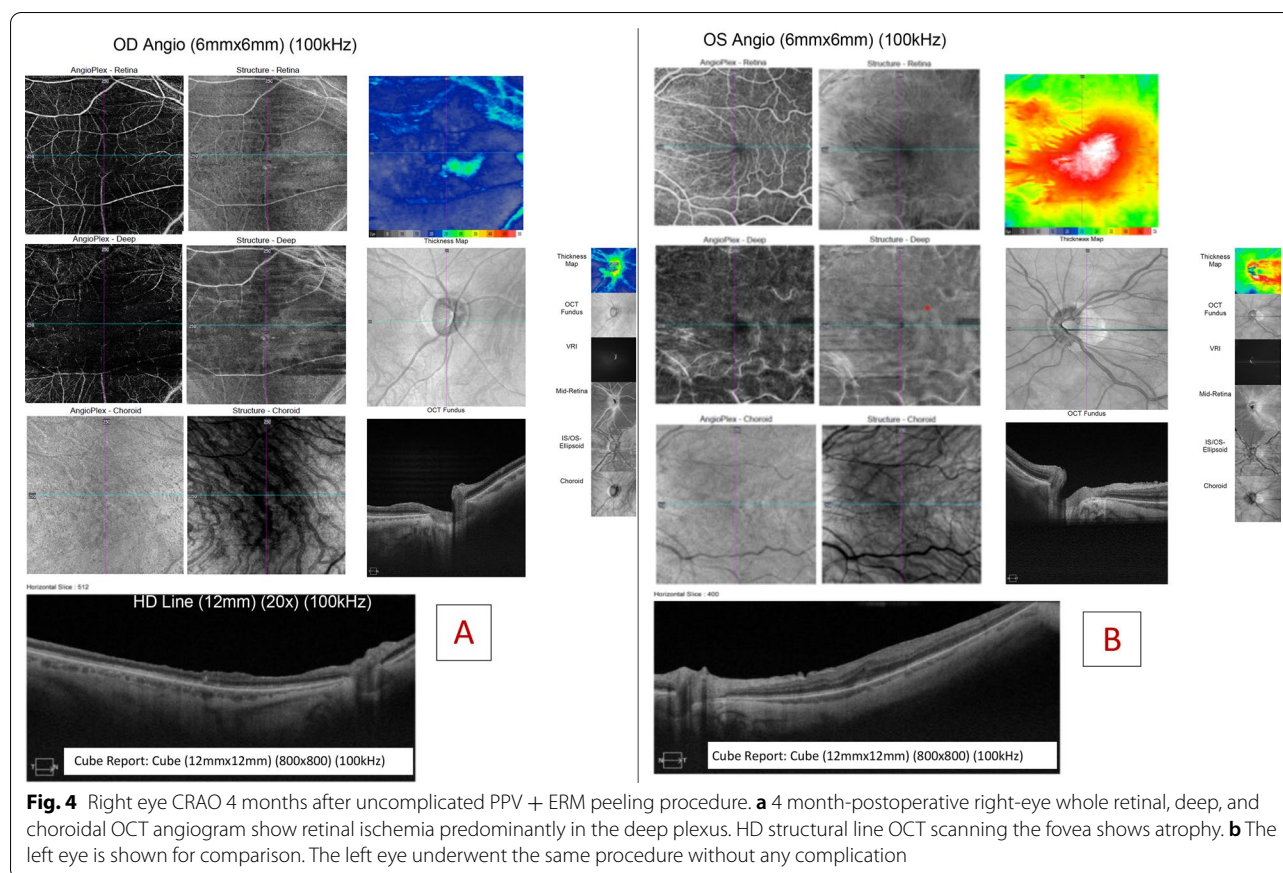


Fig. 3 Right eye CRAO 3 months after PPV + ERM peeling procedure. **a** Three-month postoperative wide-field fundus photograph and of right eye showed reduction of retinal whitening and disappearance of cherry red spot. **b** Three-month postoperative fundus autofluorescence image. **c** Three-month postoperative macular cross-sectional OCT shows atrophic foveal region and difficulty in central fixation

Preoperative review of the patient's medical history showed that the patient was under observation due to a myocardial infarction that he had about 5 years previously. He also was under rheumatological observation for ankylosing spondylitis. His treatment at the time of surgery consisted of acetylsalicylic acid 75 mg once daily and atorvastatin 40 mg once daily. No other health problems were reported. The patient denied any allergies. The patient's social history was negative for smoking, alcohol abuse, recreational drug use, and travel abroad. The patient was a doctor who had been worked in the hospital as a clinician for about 30 years. His mother suffered from migraines and died of a heart attack at the age of 70 years. At the age of 69 years, his maternal grandfather suffered a stroke. The patient did not know anything about his father's side of the family, but there was no other family history of stroke or vascular illness.

Three 25G trocars were placed through a self-sealing sclerotomy construction. Central and peripheral pars plana vitrectomy (PPV) was performed. Preexisting posterior vitreous detachment (PVD) induction was verified. Brilliant Blue G containing dye (ILM-BLUE®; D.O.R.C., Zuidland, the Netherlands) aided visualization of the internal limiting membrane (ILM) and allowed for both ERM and ILM peeling up to the vascular arcades. Peripheral indentation allowed for retinal lesion verification. No breaks were found. BSS intraocular irrigating solution was left in the vitreous chamber. The sclerotomies were self-sealing and no sutures were needed. At the conclusion of the procedure, about 0.2 mg of subconjunctival gentamycin was administered. No gas bubble was instilled, there were no episodes of hypotension during the surgery, and postoperatively the patient did not sleep in the prone position.



The left eye had a regular postoperative course (Fig. 1a, b). On postoperative day 1 the patient was seen by a junior ophthalmologist, and the visual acuity (VA) in the right eye was hand motion. Intraocular pressure (IOP) was 14 mmHg. There was a trace afferent pupillary defect by reverse in the right eye. The posterior segment examination showed retinal whitening in the macula and a cherry-red spot (Fig. 2a, b).

The retina was attached. There was no proptosis or orbital fullness. Optical coherence tomography (OCT) demonstrated inner retinal thickening and hyperreflectivity (Fig. 2c). Fluorescein angiography demonstrated delayed arterial and venous perfusion (not shown).

No further systemic evaluation was performed, the patient was observed and was not referred to a stroke center by the junior ophthalmologist. No blood tests were carried out. No blood pressure, pulse nor temperature was recorded. The patient was not treated with anterior chamber paracentesis, timolol-dorzolamide and brimonidine drops, or 500 mg oral acetazolamide at the first day postoperative control. The patient was alert, attentive, and oriented. Speech was clear and fluent. Cranial nerve assessment, reflexes, sensory perception, coordination,

and gait were all normal. No signs of cerebrovascular event were reported.

At 3 months after surgery, the patient felt his central scotoma had improved, and the BCVA had remained stable at 0.05 (− 0.75 to 1.0 axis 60). The anatomical signs of acute ischemia had resolved, and the macular region resulted in atrophic changes with disappearance of the physiological foveal depression (Fig. 3).

At 4 months after surgery, OCT angiography documented a right eye capillary dropout predominantly in the deep capillary plexus (Fig. 4)

Discussion and conclusions

We report a patient with CRAO that occurred in the postoperative period after vitreoretinal surgery with PPV + ERM peeling. Both eyes underwent the same procedure 3 months apart by the same experienced surgeon, but only the second eye showed CRAO.

Many authors have previously described the occurrence of CRAO after retrobulbar anesthesia, as summarized in Table 1.

CRAO is a known, but very rare complication of ocular surgery that can occur after retrobulbar, peribulbar,

Table 1 Summary of previous reports of central retinal artery occlusion after retrobulbar anesthesia

Study	Age (years), gender	Cardiovascular risk factors	Diagnosis	Procedure	Therapy	Time to treatment or examination (days)	Preoperative Visual Acuity	Postoperative Early Visual Acuity	Postoperative Final Visual Acuity	Follow-up (days)
Klein et al. [14]	19, F	DM	PDR	Photocoagulation	Ocular massage	Immediately	20/50	FC	20/30	7
	43, F	hemoglobinopathy	SCR with secondary glaucoma	Phaco + IOL	Ocular massage	Immediately	NA	HM	20/20	3
	33, F	Sickle-cell hemoglobinopathy	Carotid insufficiency	Cataract extracapsular	None	Immediately	20/40	FC	20/50	1
	59, M	hemoglobinopathy	Carotid insufficiency	Photocoagulation	AC paracentesis		20/50	NA		
Sullivan et al. [36]	60, M	Acetylsalicylic acid daily	Cataract	Phaco + IOL	Kronlein lateral orbitotomy with nerve sheath decompression, carbon dioxide inhalation, lowering IOP Mx	6	20/60	20/60	6/60	6
	81, F	Acetylsalicylic acid daily	AACG	Cataract extracapsular	orbitotomy with nerve sheath decompression, carbon dioxide inhalation, lowering IOP Mx	2	NA	NLP	NLP	0
	67, F	Acetylsalicylic acid daily	NA	Phaco + IOL	None	4	20/32	20/200		7
				implantation Surgical iridectomy	None					
Cowley et al. [35]	30, F	DM	PDR	Photocoagulation	Ocular massage, AC paracentesis, sublingual nitroglycerin, inhalation of carbon dioxide	Immediate	20/80	NA	NA	NA
Mieler et al. [15]	34, F	None	Cataract	Phaco + IOL	None	1	NA	LP	HM	150
Roth et al. [34]	38, M	Sickle-cell hemoglobinopathy	Proliferative SCR	Photocoagulation	None	Immediately	NA	HM	HM	365
Giuffre et al. [13]	61, M	HTN	Cataract	Extracapsular cataract extracapsular	None	3	NA	LP	NLP	14
Torres et al. [33]	74, F	None	Cataract	Extracapsular cataract extracapsular	None	1	1	NA	LP	CRVO
	66, F	None	Cataract	Extracapsular cataract extracapsular	None	1	1	NA	LP	CRVO
Mameletzi et al. [32]	78, F	None	Cataract	Phaco + IOL	Lowering IOP Mx, anticalcic therapy, methylprednisolone	1	NA	LP	HM	30

Table 1 (continued)

Study	Age (years), gender	Cardiovascular risk factors	Diagnosis	Procedure	Therapy	Time to treatment or examination (days)	Preoperative Visual Acuity	Postoperative Early Visual Acuity	Postoperative Final Visual Acuity	Follow-up (days)
Tappeiner et al. [31]	58, M 79, M 83, F	HTN, HTN, aorta aneurysm	Macular pucker Macular hole Vitreous hemorrhage	Vitrectomy Vitrectomy Vitrectomy	Lowering IOP Mx Lowering IOP Mx Lowering IOP Mx	2-14 2-14 2-14	NA NA NA	NA NA NA	20/320 LP 20/200	365 365 365
Jung et al. [2]	72, M 72, F 53, F 72, M 66, F	HTN, cerebral infarction HTN, DM, ICA stenosis, MI HTN, DM, ESRD, cerebral infarction HTN	Cataract VH VH Macular pucker Cataract	Phaco + iol PPV PPV PPV Phaco + IOL	Intraarterial thrombolysis Intraarterial thrombolysis Anterior chamber paracentesis, lowering IOP Mx None intraarterial thrombolysis	1 1 7 1 1	NLP NLP HM HM HM	NA	NLP LP NLP FC FC	1367 4 1577 1807 942
Vasavada et al. [4]	65, F 46, F	DM, HTN	Cataract	MSICS Phaco + IOL	Ocular massage, AC paracentesis, IOP lowering drops None	1 30	NA NA	NA NA	CF CF	NANA
Fischer et al. [30]	72, F 63, M 69, M	None DM	MH with several peripheral retinal degenerations Cataract RRD	Encircling band, PPV, C2F6 (10%) Phaco + IOL PPV, encircling band, C2F6 (14%)	None None None	19 69 21	0.4 0.5 0.1	NA NA NA	HM 1.0 HM	NA NA NA
Russell et al. [1]	28, M 70, F	Familiarity for MI HTN	RRD Vitreous opacities	PPV	AC tap, timolol-dorzolamide, brimonidine, hyper-ventilation None	1 1	20/15 20/25	LP 3/200		300 180
Confalonieri et al. [29]	67, M	History of MI	Macular pucker	PPV + peeling ERM	None	1	0.5	0.05		120

AC anterior chamber, CF counting finger, DM diabetes mellitus, ERM epiretinal membrane, ESRD end-stage renal disease, F female, FC finger counting, HM hand motion, HTN arterial hypertension, ICA internal carotid artery, IOL intraocular lens, IOP intraocular pressure, LP light perception, M male, MH macular hole, MI myocardial infarction, NLP no light perception, OIS ocular ischemic syndrome, PPV pars plana vitrectomy, RRD regmatogenous retinal detachment, SCR sickle cell retinopathy

or sub-Tenon's anesthesia [1–14]. It is also a known, but very rare complication of adrenaline injection as an adjuvant in anesthesia administration in other parts of the body, especially in ear, nose and throat, oral, and plastic surgery [14–20]. To our knowledge, this is the first report to associate retrobulbar anesthesia injection combined with adrenaline to CRAO.

We suspect that multiple factors related to the adrenaline injection might have contributed to the development of this case. Since CRAO can happen after retrobulbar anesthetic injection even in absence of adrenaline, however, this might just be one of those rare cases of increased intraorbital pressure in a patient affected by vasculopathy resulting in ischemia.

Since adrenaline can cause CRAO following trigeminal nerve block during oral procedures or local anesthesia of the nasal mucosa during nasal surgery [14–20], the proposed mechanism is arterial occlusion resulting from either direct or indirect mechanical trauma with subsequent vasospastic events or intraarterially injected adrenaline with retrograde migration [20, 23–27]. The Atkinson needle has a blunt tip and would be expected to cause minimal trauma to the surrounding tissue.

Adrenaline acts peripherally on α -adrenergic receptors [28], resulting in the constriction of blood vessels. Thus, in our case, retrograde arterial migration of the injected adrenaline into the ophthalmic arterial system might have blocked the ophthalmic artery immediately after injection. Through vasodilation over time, subsequent anterior movement of adrenaline to more distal vessels may have led to vasoconstriction and subsequent vasospasm.

We exclude the hypothesis of allergic reaction to adrenaline, even though sensitization could have happened after the first vitreoretinal operation, because of lack of systemic symptoms.

Adrenaline can lead to CRAO following retrobulbar injection of intraconal administered local anesthetics. Hence, physicians should carefully administer local anesthesia with adrenaline in the intraconal space while considering the possibility that such a complication may occur, or possibly exclude anesthetics containing adrenaline during retrobulbar anesthesia.

Abbreviations

BCVA: Best corrected visual acuity; CRAO: Central retinal artery occlusion; ERM: Epiretinal membrane; G: Gauge; ILM: Internal limiting membrane; IOP: Intraocular pressure; PPV: Pars plana vitrectomy; PVD: Posterior vitreous detachment; VA: Visual acuity.

Acknowledgements

Not applicable.

Author contributions

FC wrote the manuscript and constructed the table and figures. GP provided surgical care to the patient and supervised the whole work. GEL and ISJ reviewed and approved the paper. All authors read and approved the final manuscript.

Funding

No funding was received for this work.

Availability of data and materials

Data and material can be found at the Oslo University Hospital, Ophthalmology Department.

Declarations

Ethics approval and consent to participate

Written approval for this case report was issued by the relevant authorities of the Oslo University Hospital.

Consent for publication

Written informed consent was obtained from the patient for publication of this case report and any accompanying images. A copy of the written consent is available for review by the Editor-in-Chief of this journal.

Competing interests

No conflict of interest exists.

Author details

¹Department of Ophthalmology, Oslo University Hospital, Kirkeveien 166, 0450 Oslo, Norway. ²Center for Eye Research, Department of Ophthalmology, Institute for Clinical Medicine, University of Oslo, Kirkeveien 166, 0450 Oslo, Norway. ³Department of Biomedical Sciences, Humanitas University, Via Rita Levi Montalcini 4, 20090 Pieve Emanuele, Milan, Italy. ⁴Department of Ophthalmology, University of Split School of Medicine and University Hospital Centre, Split, Croatia.

Received: 7 April 2022 Accepted: 4 July 2022

Published online: 09 August 2022

References

- Russell JF, Scott NL, Haddock LJ, Eaton AM, Flynn HW. Central retinal artery occlusion on postoperative day one after vitreoretinal surgery. *Am J Ophthalmol Case Rep.* 2018;12:93–6. <https://doi.org/10.1016/j.ajoc.2018.10.001>.
- Jung EH, Park KH, Woo SJ. Iatrogenic central retinal artery occlusion following retrobulbar anesthesia for intraocular surgery. *Korean J Ophthalmol.* 2015;29(4):233. <https://doi.org/10.3341/kjo.2015.29.4.233>.
- Deshmukh R, Narula R. Commentary: central retinal arterial occlusions after phacoemulsification: our perspective. *Indian J Ophthalmol.* 2019;67(5):633–4. https://doi.org/10.4103/ijo.IJO_280_19.
- Vasavada D, Baskaran P, Ramakrishnan S. Retinal vascular occlusion secondary to retrobulbar injection: case report and literature review. *Middle East Afr J Ophthalmol.* 2017;24(1):57. https://doi.org/10.4103/meajo.MEAJO_37_16.
- Ellabban AA, Patil AD, Costen MT, Babar AR. Central retinal artery occlusion during vitrectomy: immediate retinal revascularization following induction of posterior vitreous detachment. *Am J Ophthalmol Case Rep.* 2018;9:38–40. <https://doi.org/10.1016/j.ajoc.2018.01.008>.
- Feibel RM, Guyton DL. Transient central retinal artery occlusion after posterior sub-Tenon's anesthesia. *J Cataract Refract Surg.* 2003;29(9):1821–4. [https://doi.org/10.1016/S0886-3350\(02\)01975-2](https://doi.org/10.1016/S0886-3350(02)01975-2).
- Ascaso FJ. Transient central retinal artery occlusion following peribulbar anesthesia for pars plana vitrectomy. *J Clin Anesth.* 2010;22(7):577–8. <https://doi.org/10.1016/j.jclinane.2010.02.010>.

8. Calenda E, Rey N, Compere V, Muraine M. Peribulbar anesthesia leading to central retinal artery occlusion. *J Clin Anesth*. 2009;21(4):311–2. <https://doi.org/10.1016/j.jclinane.2008.11.006>.
9. Lamichhane G, Gautam P. Central retinal arterial occlusion (CRAO) after phacoemulsification—a rare complication. *Nepal J Ophthalmol*. 2013;5(2):281–3. <https://doi.org/10.3126/nepjoph.v5i2.8746>.
10. Rodríguez Villa S, Salazar Méndez R, Cubillas Martín M, Cuesta GM. Central retinal artery occlusion after phacoemulsification under peribulbar anaesthesia: pathogenic hypothesis. *Archivos de la Sociedad Española de Oftalmología (English Edition)*. 2016;91(1):40–3. <https://doi.org/10.1016/j.oftale.2015.12.009>.
11. Vinerovsky A, Rath EZ, Rehany U, Rumelt S. Central retinal artery occlusion after peribulbar anesthesia. *J Cataract Refract Surg*. 2004;30(4):913–5. <https://doi.org/10.1016/j.jcrs.2003.08.021>.
12. Brod RD. Transient central retinal artery occlusion and contralateral amaurosis after retrobulbar anesthetic injection. *Ophthalmic Surg Lasers Imaging Retina*. 1989;20(9):643–6. <https://doi.org/10.3928/1542-8877-19890901-07>.
13. Giuffrè G, Vadala M, Manfrè L. Retrobulbar anesthesia complicated by combined central retinal vein and artery occlusion and massive vitreo-retinal fibrosis. *Retina*. 1995;15(5):439–41.
14. Klein ML, Jampol LM, Condon PI, Rice TA, Serjeant GR. Central retinal artery occlusion without retrobulbar hemorrhage after retrobulbar anesthesia. *Am J Ophthalmol*. 1982;93(5):573–7. [https://doi.org/10.1016/S0002-9394\(14\)77371-4](https://doi.org/10.1016/S0002-9394(14)77371-4).
15. Mieler WF, Bennett SR, Platt LW, Koenig SB. Localized retinal detachment with combined central retinal artery and vein occlusion after retrobulbar anesthesia. *Retina*. 1990;10(4):278–83.
16. Tappeiner C, Garweg JG. Retinal vascular occlusion after vitrectomy with retrobulbar anesthesia—observational case series and survey of literature. *Graefes Arch Clin Exp Ophthalmol*. 2011;249(12):1831–5. <https://doi.org/10.1007/s00417-011-1783-9>.
17. Maaranen TH, Mäntyjärvi MI. Central retinal artery occlusion after a local anesthetic with adrenaline on nasal mucosa. *J Neuroophthalmol*. 2000;20(4):234–5.
18. Savino PJ, Burde RM, Mills RP. Visual loss following intranasal anesthetic injection. *J Clin Neuroophthalmol*. 1990;10(2):140–4.
19. De Keyser K, Tassignon MJ. Case report: acute unilateral loss of visual acuity after a visit to the dentist: an unusual complication after the use of an anesthetic combined with adrenaline. *Rev Belge Med Dent* (1984). 2004;59(1):30–3.
20. Leng T, Moshfeghi DM. Branch retinal artery occlusion after septoplasty. *Ophthalmic Surg Lasers Imaging*. 2010;41:e1–2. <https://doi.org/10.3928/15428877-20101124-13>.
21. Rettinger G, Christ P, Meythaler FH. Blindness caused by central artery occlusion following nasal septum correction. *HNO*. 1990;38(3):105–9.
22. Yang JJ, Li WY, Jil Q, et al. Local anesthesia for functional endoscopic sinus surgery employing small volumes of epinephrine-containing solutions of lidocaine produces profound hypotension. *Acta Anaesthesiol Scand*. 2005;49(10):1471–6. <https://doi.org/10.1111/j.1399-6576.2005.00869.x>.
23. Guler Alis M, Acikalin B, Alis A, Ucal YO. Transient retinal artery occlusion after uncomplicated rhinoplasty. *J Craniofac Surg*. 2019;30(3):e221. <https://doi.org/10.1097/SCS.00000000000005180>.
24. Günay C, Altin G, Kersin B, Odabaşı M. A rare complication after septoplasty: visual loss due to right retinal artery spasm. *J Craniofac Surg*. 2018;29(2):466–8. <https://doi.org/10.1097/SCS.00000000000004202>.
25. Plate S, Asboe S. Blindness as a complication of rhinosurgery. *J Laryngol Otol*. 1981;95(3):317–22. <https://doi.org/10.1017/s0022215100090757>.
26. Midilli R, Palamar M, Akyıldız S, Göde S. Diplopia secondary to septal infiltration anesthesia: two cases. *Kulak Burun Bogaz Ihtis Derg*. 2010;20(1):48–50.
27. Kim HD, Lim SC. Transient abducens nerve palsy during endoscopic sinus surgery: report of three cases. *Auris Nasus Larynx*. 2007;34(2):237–9. <https://doi.org/10.1016/j.anl.2006.07.008>.
28. Taylor BN, Cassagnol M. Alpha adrenergic receptors. StatPearls Publishing; 2021. <https://www.ncbi.nlm.nih.gov/books/NBK539830/>. Accessed 31 Oct 2021.
29. Confalonieri F, Elin Ladstein G, Stene-Johansen I, Petrovski G. Iatrogenic Central Retinal Artery Occlusion Following Retrobulbar Anesthesia with adrenaline for VitreoRetinal Surgery. *J Med Case Rep*. 2022. <https://doi.org/10.1186/s13256-022-03518-0>.
30. Fischer C, Bruggemann A, Hager A, Callizo Planas J, Roeder J, Hoerauf H. Vascular Occlusions following Ocular Surgical Procedures: A Clinical Observation of Vascular Complications after Ocular Surgery. *J Ophthalmol*. 2017;2017:1–6. <https://doi.org/10.1155/2017/9120892>.
31. Tappeiner C, Garweg JG. Retinal vascular occlusion after vitrectomy with retrobulbar anesthesia—observational case series and survey of literature. *Graefes Arch Clin Exp Ophthalmol*. 2011;249(12):1831–5. <https://doi.org/10.1007/s00417-011-1783-9>.
32. Mameletzi E, Pournaras J-A, Ambresin A, Nguyen C. Retinal Embolisation with Localised Retinal Detachment following Retrobulbar Anaesthesia. *Klinische Monatsblätter für Augenheilkunde*. 2008;225(5):476–8. <https://doi.org/10.1055/s-2008-1027268>.
33. Torres RJA, Luchini A, Weis W, Freccero PR, Casella M. Oclusão artério-venosa da retina após bloqueio retrobulbar: relato de dois casos. *Arquivos Brasileiros de Oftalmologia*. 2005;68(2):257–61. <https://doi.org/10.1590/S0004-27492005000200020>.
34. Roth SE, Magargal LE, Kimmel AS, Augsburger JJ, Morrison DL. Central retinal-artery occlusion in proliferative sickle-cell retinopathy after retrobulbar injection. *Ann Ophthalmol*. 1988;20(6):221–4.
35. Cowley M, Campochiaro PA, Newman SA, Fogle JA. Retinal vascular occlusion without retrobulbar or optic nerve sheath hemorrhage after retrobulbar injection of lidocaine. *Ophthalmic Surg*. 1988;19(12):859–61.
36. Sullivan KL, Brown GC, Forman AR, Sergott RC, Flanagan JC. Retrobulbar anesthesia and retinal vascular obstruction. *Ophthalmology*. 1983;90(4):373–7. [https://doi.org/10.1016/s0161-6420\(83\)34547-4](https://doi.org/10.1016/s0161-6420(83)34547-4).

Publisher's Note

Springer Nature remains neutral with regard to jurisdictional claims in published maps and institutional affiliations.

Ready to submit your research? Choose BMC and benefit from:

- fast, convenient online submission
- thorough peer review by experienced researchers in your field
- rapid publication on acceptance
- support for research data, including large and complex data types
- gold Open Access which fosters wider collaboration and increased citations
- maximum visibility for your research: over 100M website views per year

At BMC, research is always in progress.

Learn more biomedcentral.com/submissions

